

| Total Comfort | Relief | Ease (maintenance) | Transcendence |
|-------------------------|-----------------------------------------------------------------------------------------------------------------------------------------------|------------------------------------------------------------------------------------------------------------|---------------------------------------------------------------------------------------------------------------------------------------------------|
| Physical | Hyperglycemia Hunger, weight loss Diminished vision | Normal BS Optimal weight Skin healed Pain managed without narcotics?) | Wants to be best possible diabetic patient with excellent BS control |
| Psycho-spiritual | Anxiety, Anger, Why us? How will we manage? | Adherence, confidence, faith | Engages in exercise & HSBs; motivated to learn & grow |
| Socio-cultural- | Need to understand diet, blood sugar, sequelae Financial distress, body image challenged Anxiety of wife, need for reassurance, rituals | Understands regimen & diet; social service helping w paperwork; uses phone to connect; self esteem healthy | Social support system inspires and gives material and emotional aid naturally & consistently; nurse as trusted source of advice and interventions |
| Environ-mental | Transportation difficult; wait room crowded & cluttered; wait for appt. prolonged | Quality of office furniture, decorating patient friendly Wait time minimal | Vouchers for Bus/taxi or van transport ; peaceful view or hopeful posters |

CLIENT: Mr. Simon Dawkins
AGE: 45

Priority Nursing Care Plan
Developed On One Priority Problem
Assessment done according to Head-to-Toe Model

| Ordered & Selected Data | Nursing Diagnosis | Goals | Interventions | Rationale | Evaluation |
|------------------------------------------------------------------------------------------------------------------------------------------------------------------------------------------------------------------------------------------------------------------------------------------------------------------------------------------------------------------------------------------------------------------------------------------------------------------------------------------------------|----------------------------------------------------------------------------------------------------------------------------------------------------------------------------------------------------------------------------------------------------------------------------------------------------------------------------|---------------------------------------------------------------------------------------------------------------------------------------------------------------------------------------------------------------------------------------------------------------------------------------------------------------------------------------------------|-------------------------------------------------------------------------------------------------------------------------------------------------------------------------------------------------------------------------------------------------------------------------------------------------------------------------------------------------------------------------------------------------------------------------------------------------------------------------------------------------------------------------------------------------------------------|-----------------------------------------------------------------------------------------------------------------------------------------------------------------------------------------------------------------------------------------------------------------------------------------------------------------------------------------------------------------------------------------------------------------------------------------------------------------------------------------------------------------------------------------------------------------------------|--------------------------------------------------------------------------------------------------------------------------------------------------------------------------------------------------------------------------------------------------------------------------------------------------------------------------------------------------------------------------|
| <p>Subjective data: Client sustained wound a week ago after a stone crushed right foot, washed wound with old washcloth, area has gotten worse, full of pus.</p> <p>Objective data: Foot wrapped in old soiled towel, (blood stains on towel). Wound approximately 10 centimeters wide and two centimeters deep. Area hyperemic, swollen, painful to touch. Client displays limited functioning of extremity, catarrhal and purulent exudate with some fibrinous leakage, odororous.</p> | <p>Infection, acute, related to trauma evidenced by open wound, redness, pain, heat, and exudate (catarrhal, purulent, and fibrinous), edema dysfunction and cultured organism (staphylococcus aureus).</p> <p>Defining characteristics: Redness, heat, pain, swelling, and loss of function, inflammatory exudate</p> | <p>Short term: Client will state that he is more comfortable at least one half an hour after intervention. Drainage will be lessening on first day of admission and temperature will decrease (99.0° F).</p> <p>Long term: Drainage will steadily decrease by second day of admission; wound will begin to show signs of healing.</p> | <ul style="list-style-type: none"> Elevate affected leg on pillow. Give pain medication. Use Debrisan and dressing 3 times a day. Use aseptic technique. Teach client about the infectious process and illness prevention. Provide balanced diet high in vitamin C and B; encourage 6 to 8 glasses of water a day. May collaborate for hydrocolloid dressing (duoderm). Leave on for 7 days; remove only when there is leakage around the edges. Administer antibiotics as ordered. | <ul style="list-style-type: none"> Elevation and rest will decrease inflammation, reduce edema pain, and increase blood flow into the affected area. Analgasic reduces pain. Debrisan removes dead tissues and absorbs exudate. Prevents recontamination. Provides a knowledge base for cure. Builds a strong immune system, aids with healing, water removes impurities and equalizes body temperature. Protects formation of new cells, encourages tissue growth. Destroys bacterial growth | <p>Short-term goals met: Client admitted feeling more comfortable, half an hour after elevation of leg and analgesic administration.</p> <p>Exudate decreased in amount by the end of the shift at 1500.</p> <p>Long-term goal met: Debrisan dressing used for 2 days changed to duoderm on 3rd day; wound very clean after 7 days. Showed signs of healing.</p> |

Reference: Cox, H.C., Hinz, M., Lubno, M., Scott-Tilley, D., Newfield, S., Slater, M., & Sidoromont, K. (2002). *Clinical applications of nursing diagnosis*. Philadelphia: F.A. Davis.

Head-to-Toe Assessment

Refer to Chapter 2 “Assessment,” p. 65: Care Plan Developed after Using the Head-to-Toe Assessment model

Client’s Name: Mr. Simon Dawkins

Age: 45

Activity 1

Read the Dawkins scenario to ascertain correct identification of the client.

Activity 2

Examine the pathophysiological responses of the inflammatory process in order to teach prevention and curative measures.

Activity 3

Examine the completed assessment for Mr. Dawkins. Note the differences in previous assessment formats. Review the nursing care plan for sequencing individualization and outcome.

Activity 4

Compare the Head-to-Toe Assessment with other assessment models and develop appreciation for this approach.

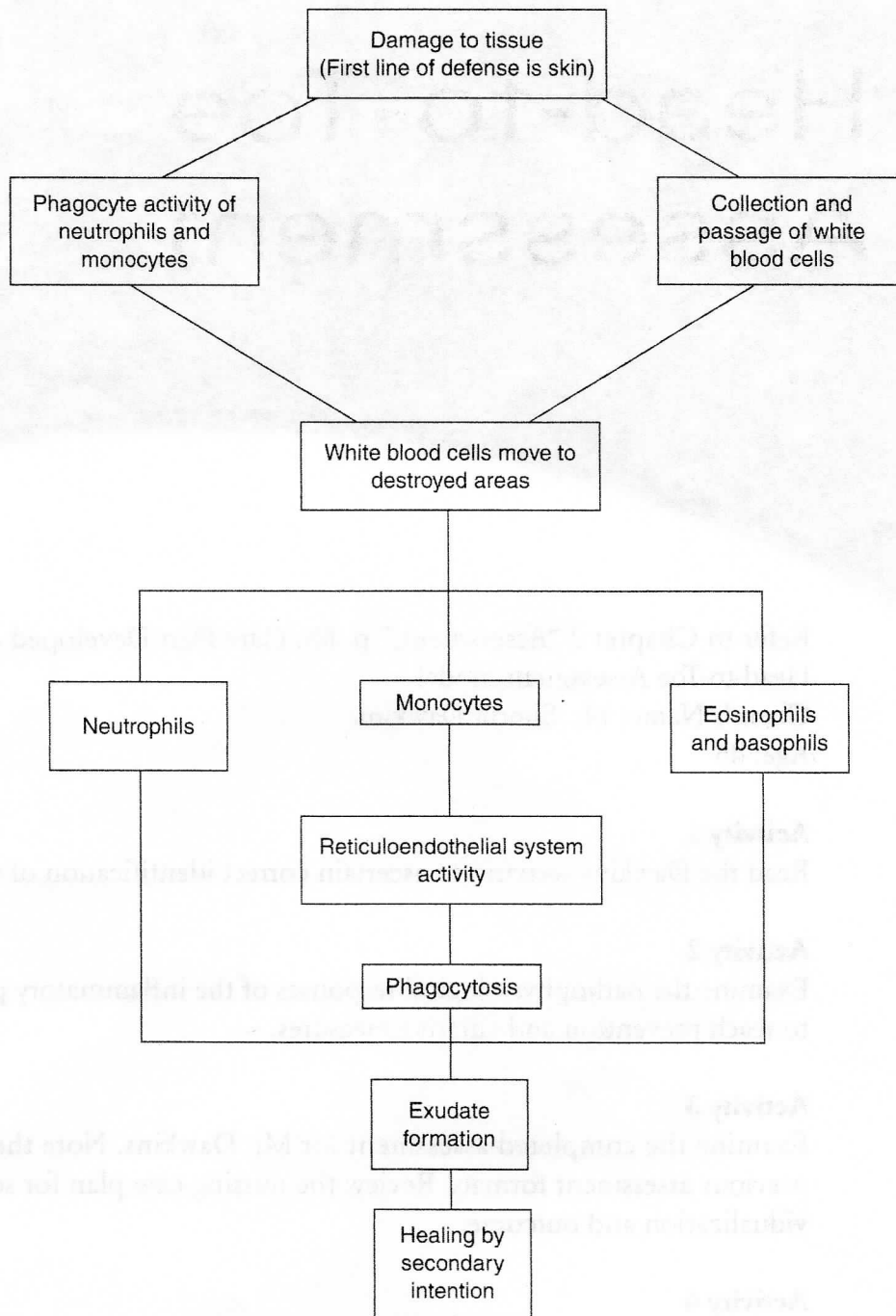


FIGURE B3-1 Pathoflow sheet showing cellular response to inflammation.

Activity 5

Examine the nursing care plan developed for Mr. Dawkins. Determine the relationship between the component parts. Identify at least two other diagnoses that would be appropriate for this client.

I. ASSESSMENT USING THE HEAD-TO-TOE APPROACH CARE PLANS DEVELOPED ON 1 PRIORITY PROBLEMS RELATES TO MR. SIMON DAWKINS**Head-to-Toe Approach****Scenario:**

Mr. Simon Dawkins is a 45-year-old male who sustained a wound to his right foot after the area was crushed by a stone. The client stated the incident happened a week ago and that he had been washing it with an old washcloth in a basin but instead of it healing it has gotten larger and full of pus. On examination the foot was wrapped in an old dirty towel that contained blotches of blood-stained drainage.

Assessment: Client Profile

Name: Mr. Simon Dawkins

Age: 45

Sex: Male

Medical Diagnosis: Infected right foot.

Vital signs:

Temperature: 101°F

Pulse: 100

Respirations: 22

Height: 5' 6"

Weight: 160 lbs. (ideal body weight 163 lbs.)

General Appearance:

Color: Pink (face flushed)

Orientation: Oriented × 3 (time, place, and person)

Dress, Grooming: Clothing soiled and crushed—shoes (boot—old and cracked) right boot tied with cord on bottom of affected foot. Hair dry and poorly maintained.

Mobility: Posture—slightly stooped to accommodate pain of right foot

Ability to stand and walk: Able to walk—moves slowly because of discomfort of right foot.

Gait and balance: Somewhat unsteady (accommodating discomfort from right foot)

Ability to perform self-care (activities of daily living): Able to perform activities of daily living but seems to lack knowledge about hygiene and the infectious process.

Skin, Hair, and Nails

Hair quality and distribution: Hair is poorly maintained and dry (on scalp) hair black on eyebrows, eyelashes, and body—neither balding alopecia nor pediculosis observed, even distribution.

Skin turgor: Skin uniformly pink (somewhat flushed), no bleeding, increased vascularity, no ecchymosis except on right foot. Right foot, skin red ecchymosis with some pink drainage with some pus.

Skin lesions: No lesions except on right foot (large infected lesion).

Palpation of skin: Moisture, dry; skin surface quite warm including hands and feet—temperature 101°F.

Texture: Skin feels smooth, even, and firm except for hair growth on chest and on right foot (ecchymosis).

Turgor: Normal (skin returns to original contour rapidly when released).

Edema: No edema present except of right foot.

Nails: Normal, pink cast, capillary refill, color returns to normal within 2 seconds.

Shape and configuration: Nail surface smooth and flat. Thickness uniform except for slight splintering of the edges.

Palpation: Nail base firm on palpation.

Head, Face, and Neck

Orientation: Client oriented to time, place, and person.

Memory: Long- and short-term memory intact.

Speech: Responds to questions and commands easily. Speech is clear and understandable. Pitch, rate, and volume normal.

Hearing:

Auditory screening

Voice—whisper test—normal (able to repeat words whispered from a distance of 2 feet).

Tuning fork tests—Weber and Rinne—Weber Test—Normal (perceives sound equally in both ears).

External Ear

Inspection—normal (matches flesh color of rest of skin [flushed]).

Positioned appropriately (positioned centrally and in proportion to the head).
Palpation: Normal (no complaints of pain or tenderness on palpation).
Otoscope Assessment: Normal—ear canal no redness, swelling, tenderness, lesions, drainage, foreign bodies, or scaly surface areas; cerumen small amount. Tympanic membrane pearly gray, light reflex at 5 o'clock in right ear and 7 o'clock in left. Blood vessels visible only on periphery. No bulging or retraction of the membrane, no evidence of fluid collection. Tympanic membrane moves when client blows against resistance.

Vision

Visual acuity: normal—20/20

Near vision: normal—able to read at a distance of 14 inches.

Color vision: Normal—able to identify primary colors found in the examining room.

Visual fields: Normal—able to see the stimulus at about 90 degrees temporal, 60 degrees nasally, 50 degrees superiority, and 70 degrees inferiority.

Eyelids: Symmetrical, no drooping, infections, or tumors of the lids. Eyebrows present bilaterally, symmetrical without lesions or scaling.

Lachrymal Apparatus

Inspection: No enlargement, swelling, or redness, small amount of exudate, minimal tearing.

Palpation: No excessive tearing or discharge from the punctum.

Extraocular Muscle Function

Corneal light reflex (Hirschberg Test): Normal—light reflex seen symmetrical in the center of each cornea.

Cover/uncover test: Eyes in alignment.

Cardinal fields of gaze (extraocular muscle movement): normal—both eyes move symmetrically and smoothly in each of the six fields of gaze; converge on head object as it moves toward the nose.

Anterior Segment Structures

Conjunctiva in bulbar: Normal—transparent with small blood vessels, no swelling, injection, exudates, foreign bodies, or lesions.

Sclera: Normal—white with small superficial vessels, no exudates, lesions or foreign bodies.

Cornea: Normal—surface moist and shiny, no discharge, cloudiness, opacities or irregularities.

Anterior Chamber: Normal—even distribution of light in anterior chamber.

Iris: normal—color evenly distributed over iris.

Pupil: normal—deep black, round, equal in diameter (approximately 4 mm.) constrict briskly to direct and sensual light and to accommodation.

Lens: normal—transparent in color.

Posterior Segment Structures

Retinal structures: Normal—red reflex present, optic disc pinkish in color with yellow-white excavated center. Four main vascular branches emanate from disc. Venules larger than arterioles and are darker in color no signs of edema or hemorrhages.

Macula: Normal—dark with pinpoint reflective center.

Mouth and Teeth

Mouth: Smells foul (halitosis probably due to poor oral hygiene).

Tongue: In midline of mouth, dorsum pink, moist, ventral portion with prominent blood vessels, no lesions present.

Lips

Inspection: Lips and membranes pink and moist, no evidence of lesions or inflammation.

Palpation: No flaccidity, no lesions palpated.

Wharton's ducts: Patent, no inflammation or lesions. Lateral aspect pink, smooth, without lesion.

Buccal mucosa: Pink, moist, smooth, and without lesions.

Teeth: Thirty-two teeth in place, several caries noted.

Palate: Hard and soft palate concave and pink, no lesions or malformations noted.

Inspection of throat: Soft palate and uvula rises symmetrically when client says "Ah," uvula midline, throat pink and vascular without swelling, exudates or lesions. Gag reflex present, tonsils XI (visible).

Cranial Nerves

I. Normal findings (able to distinguish various odors).

II. Visual acuity 20/30 OU, fundoscopic examination deferred.

III. Eyes deviate in direction opposite the head.

IV. Both eyes move smoothly and symmetrically in each of the six fields of gaze and converge on held object as it moves toward the nose.

- V. Masseter and temporalis muscles equally strong on palpation sensation to light touch and pain, intact bilaterally.
- VI. EOM—normal findings (both eyes move symmetrically in each of the six fields of gaze, converge on held object toward the nose, no nystagmus; pupils equal, round briskly, react to light and accommodation—PERRLA). No ptosis.
- VII. Motor component—face symmetrical. Sensory component (identifies sweet, sour, salty, and bitter tastes accurately).
- VIII. Gross hearing intact: Rinne—AC>BC, Weber O laterization.
- IX., X. Gag reflex present, speech clear, no hoarseness or nasal quality, swallows water easily.
- XI. Turns head against resistance with smooth, strong, and symmetrical movement.
- XII. Tongue in midline of the mouth symmetrical and moves freely.

Cerebella Function

Coordination

- Finger to nose, no impairment on either side.
- Finger from nose to examiner's finger—coordinated bilaterally.
- Heel to shin deferred (fractured femur).

Station

- Posture not tested, unable to stand.
- Gait not tested, unable to walk (fractured femur).
- Romberg, unable to test balance.

Reflexes—deep tendon reflexes

- Brachioradialis 2+ bilaterally, biceps 2+ bilaterally, triceps 2+ bilaterally, patella 3+ bilaterally, planter 2+ bilaterally, Achilles 2+ bilaterally, Babinski negative.

Chest

Inspection (shape of thorax): Ratio of anterior posterior diameter to the transverse diameter is 1–2 (wider from side to side than from front to back). Thorax slightly elliptical in shape.

Symmetry of Chest Wall: Shoulders and scapula at same height bilaterally, no masses detected.

Costal angle: Less than 90 degrees during exhalation at rest, widens slightly during inhalation (normal).

Angle of the ribs: Ribs articulate at 45 degrees with sternum (normal).

Intercostal spaces: No retractions or bulging.
Muscles of respiration: Using no accessory muscles.

Respiration

Rate: Respirations 18 per minute eupnea (normal breathing).
Pattern: Regular and even in rhythm.
Depth: Nonexaggerated and effortless.
Symmetry: Thorax rises and falls in unison, no paradoxical movement.
Audibility: Respirations heard few centimeters from client's nose by unaided ear (normal).
Client position: Breathes comfortably in supine, prone, and upright positions.
Mode of breathing: Inhales and exhales through nose.
Sputum: Small amount, clear, odorous, slightly thick.

Palpation

Pulsations: No pulsations felt (normal).
Masses: No masses present.
Thorax tenderness: No thorax tenderness present.
Crepitus: No crepitus palpated.
Thorax expansion: Thumb separates 4 cm. from spinal column and remains in the same plane of the 10th spinous vertebra (normal).
Tactile fremitus: Normal fremitus (buzzing on ulnar aspect of hand) at second ICS anteriorly and T1 and T2 posteriorly and at the trachea and less palpable in the periphery of the lungs (normal).
Tracheal position: Trachea midline in supra sterna notch.
Percussion: Resonant sounds over lung tissue, dull sounds over diaphragm and cardiac silhouette, flat over the ribs (normal).
Diaphragmatic excursion: On inspiration level of diaphragm at T12 and T10 on expiration normal.

Auscultation

Breath sounds: Normal—bronchial, bronchovesicular, and vesicular sounds heard (normal), no ronchi or crackles.

Abdomen Inspection

Contour: Normal (flat).
Symmetry: Normal (symmetrical bilaterally).
Pigmentation and color: Normal (uniform in color and pigmentation).
Scars: None.

Striae: None.

Respiration: Abdomen rises with inspiration and falls with expiration—no refraction.

Moves or nodules: None.

Visibility peristalsis: No visible movements of peristalsis (normal).

Umbilicus: Depressed and beneath the abdominal surface (normal).

Auscultation: Bowel sounds heard in right lower quadrant.

Vascular sounds: No audible bruits on auscultation.

Venous hum: None.

Friction rub: None.

Percussion: Dullness over liver and spleen.

Level span: No hepatomegally.

Spleen: No splenomegally.

Stomach: Tympany of gastric air bubble lower in palpation than tympany than intestines.

Palpation

Light palpation: Abdomen smooth with constant softness.

Deep palpation: No organ enlargement, abnormal masses, bulges, or swelling.

Elimination urine: Voids without difficulty.

Defecation: One to two bowel movements a day.

Genitalia Inspection

Hair distribution: No sparse areas.

Parasites: None.

Perineum and sacrococcygeal area: Smooth, free of lesions, swelling, inflammation and tenderness. No evidence of feces or mucus on the perineal skin.

Anal mucosa: Deeply pigmented, coarse, moist, and hairless; no lesions, inflammation, rash, masses, or additional openings; anal opening closed; no leakage of feces or mucus; no tissue profusion (normal).

Prostate: Gland small, smooth, mobile, and nontender, median sulcus palpable.

Extremities

Skin and nails: See independent assessment under skin and nails. See abnormalities of right foot.

Pulses: All pulses palpable 2+ (femoral popliteal, posterior tibial, and dorsalis pedis).

Reflexes: Deep tendon reflexes normal 2+ (biceps, brachioradialis, triceps, patellar, Achilles, Babinski, negative).

Strength: Equal bilaterally (except on right foot), no involuntary.
Joint mobility: Periarticular tissue around the joints are free from swelling, pain, tenderness, warmth, or nodules. Palpation reveals no grating or popping, synovial membrane not palpable.

Note—Inability to manipulate joint on right foot because of sore, swelling, pain and ecchymosis.

Capillary Refill 2+–3+ (not tested on right foot). Edema 2+–3+ on right foot (includes ankle), no edema on other areas of body.

Assessment

Diagnosis

Planning

Implementation

Evaluation