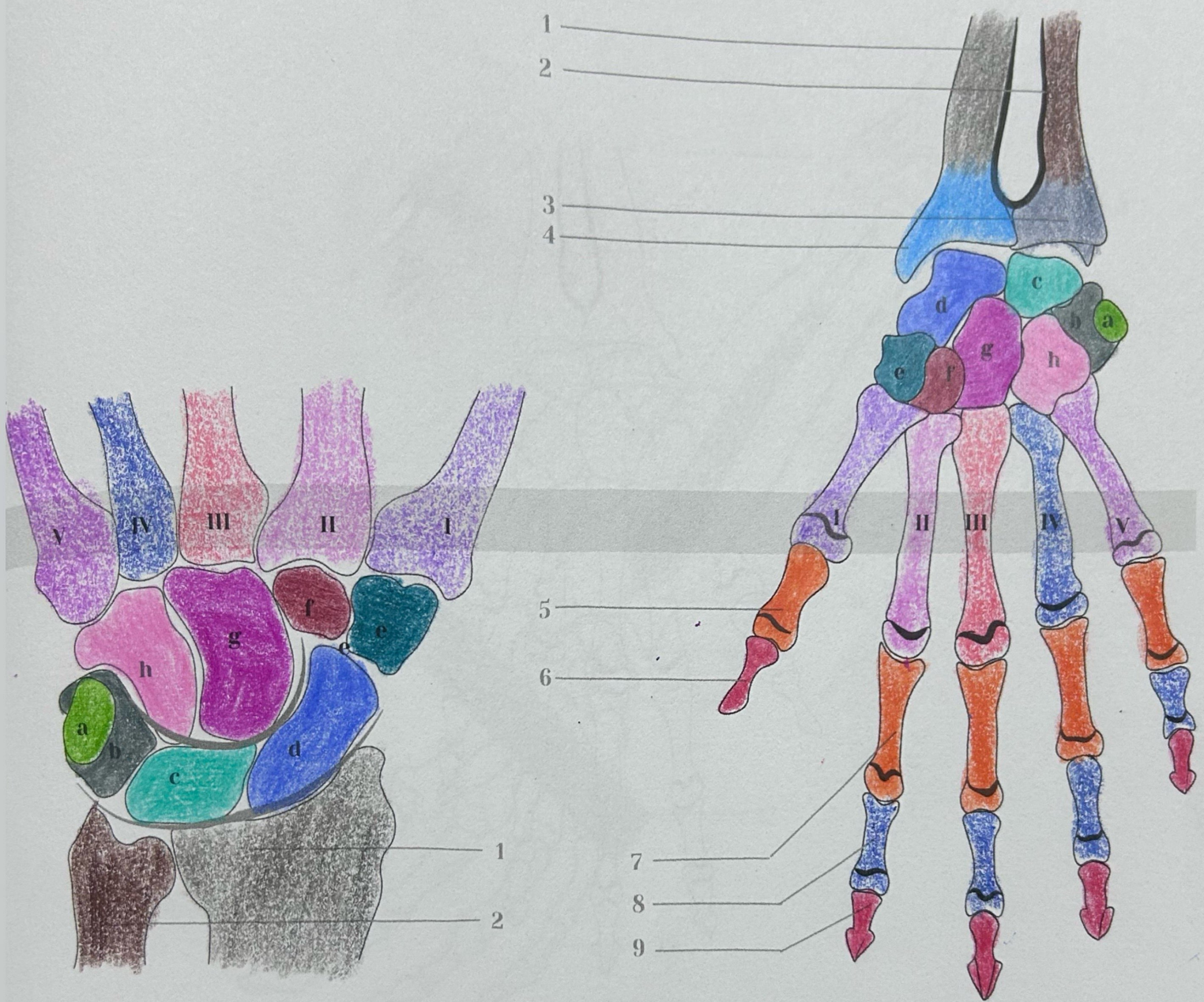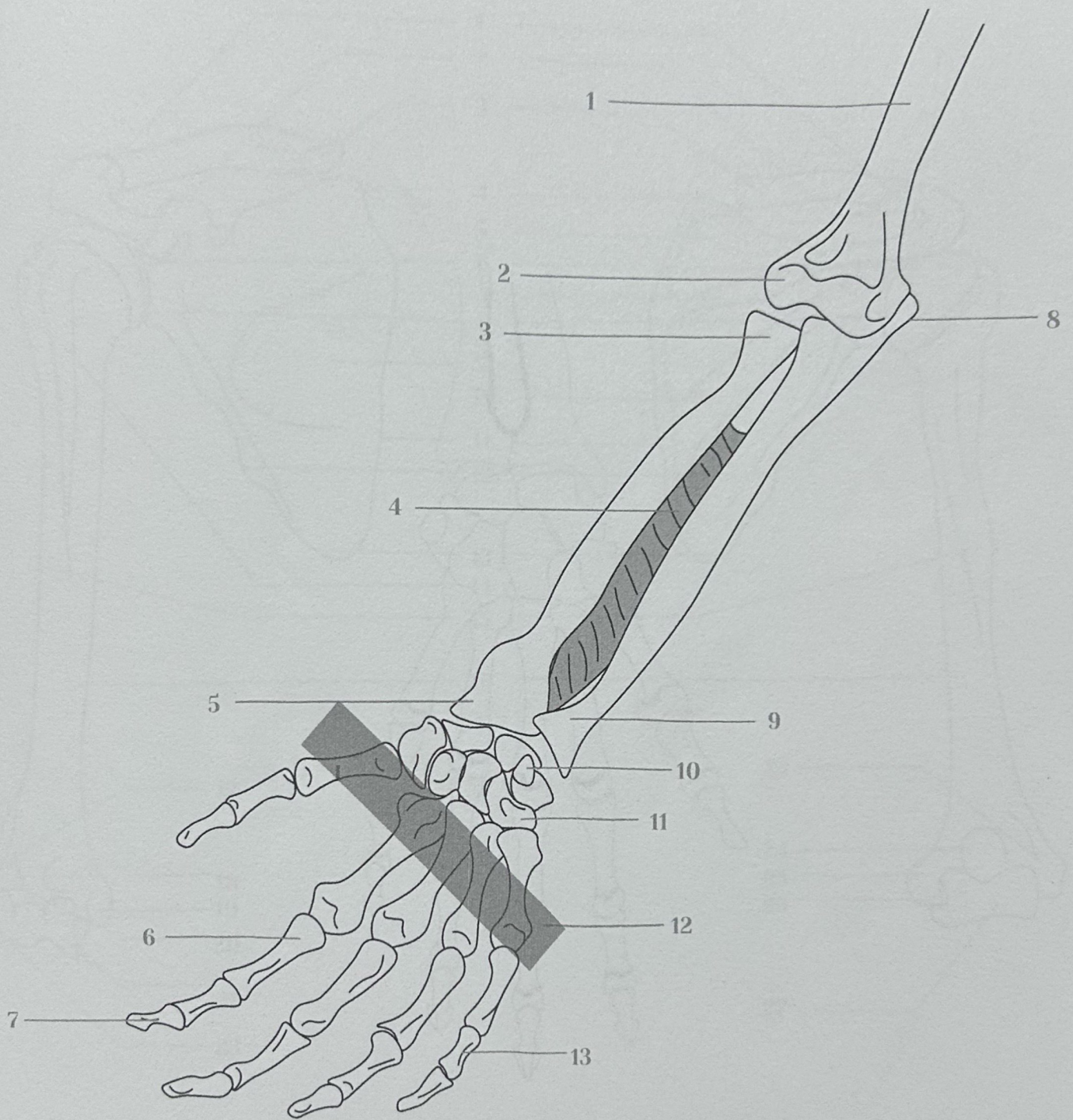


8 Carpal bones

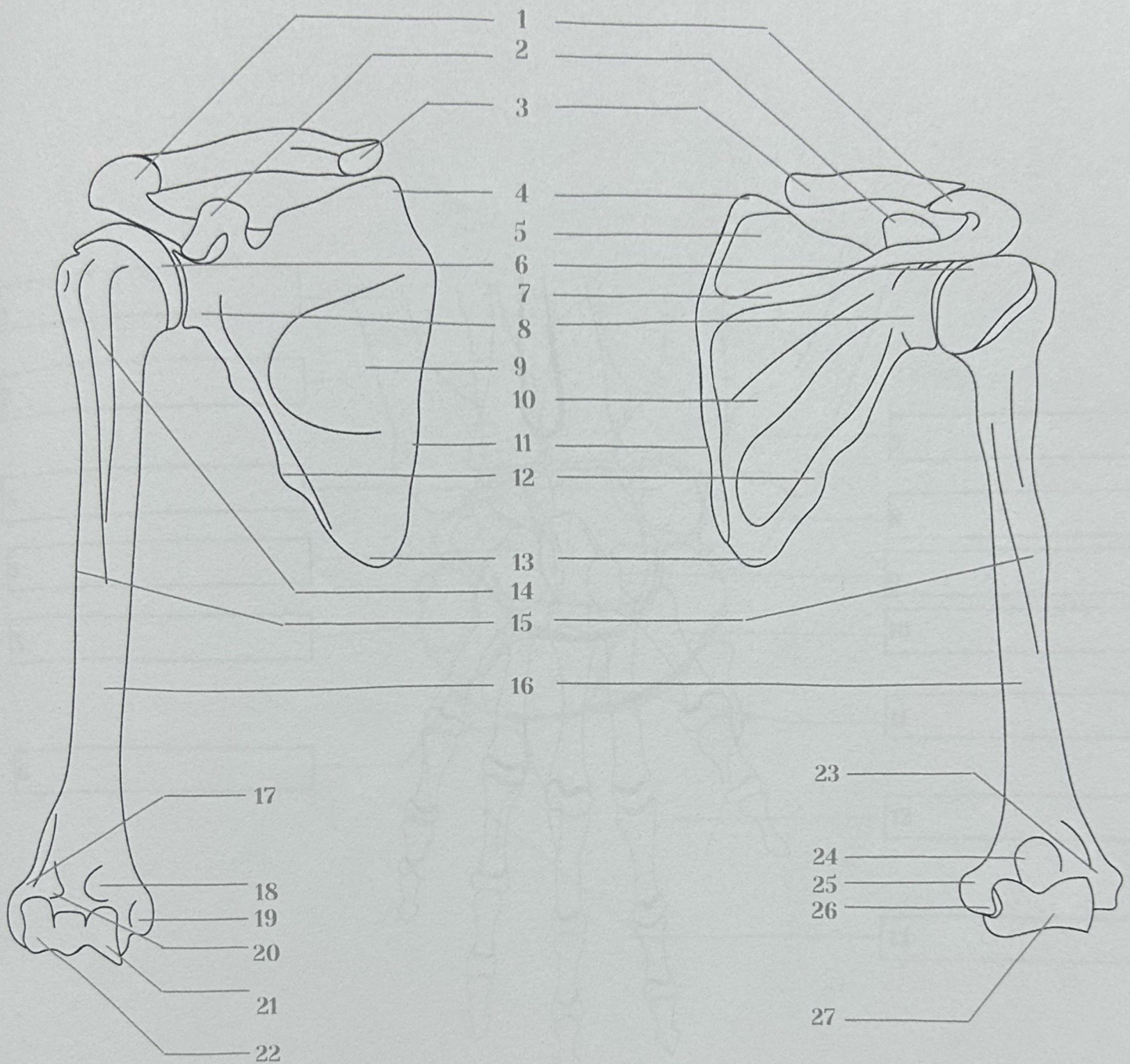
5 Metacarpal bones

- a. Pisiform
- e. Trapezium
- b. Triquetrum
- f. Trapezoid
- c. Lunate
- g. Capitate
- d. Scafoid
- h. Hamate

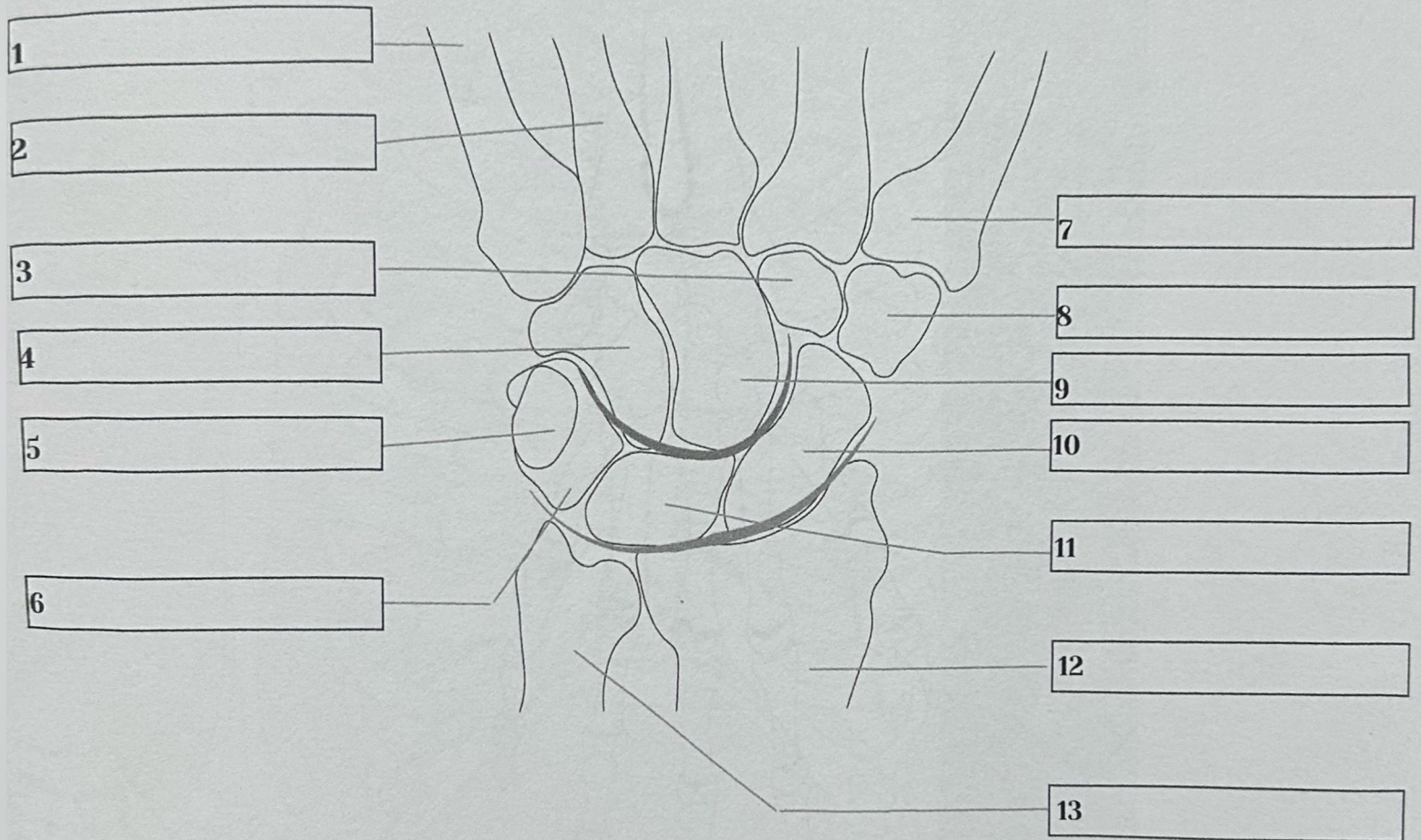
- (I) 1st Metacarpal bone
- (II) 2nd Metacarpal
- (III) 3rd Metacarpal
- (IV) 4th Metacarpal
- (V) 5th Metacarpal
- 1. Radius
- 2. Ulna
- 3. Distal head of Ulna
- 4. Styloid Process (Radius)
- 5. Proximal phalanx (I)
- 6. Distal phalanx (I)
- 7. Proximal phalanx (II)
- 8. Middle phalanx (II)
- 9. Distal phalanx (II)



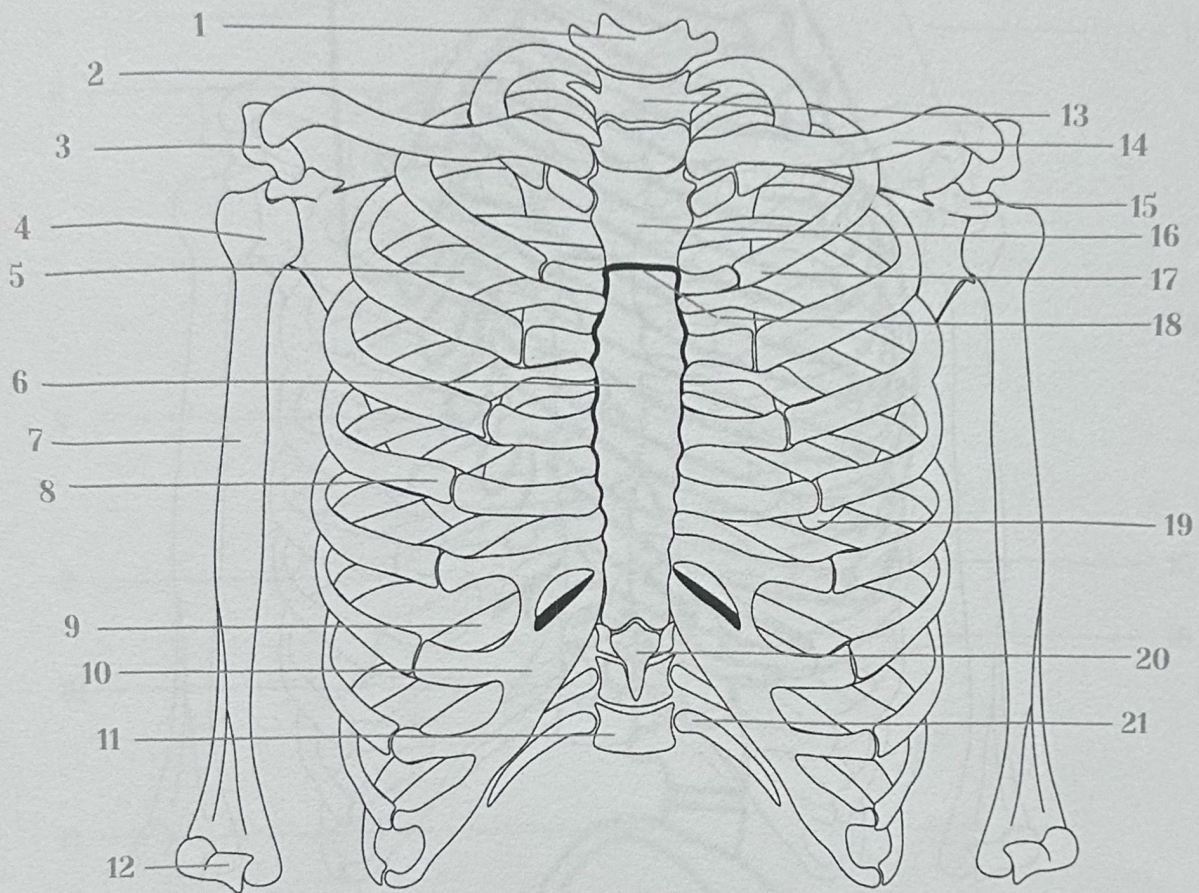
- 1. Humerus
- 2. Articular Surface
- 3. Proximal radius
- 4. Interosseous membrane
- 5. Styloid Process (Radius)
- 6. Proximal phalanx
- 7. Distal phalanx
- 8. Olecranon (Elbow)
- 9. Distal head of Ulna
- 10. Pisiform
- 11. Hamate
- 12. Metacarpal bones (x5)
- 13. Middle phalanx



- | | | |
|-------------------------|------------------------------|---------------------------------|
| ● 1. Acromion | ● 10. Infraspinous fossa | ● 19. Medial epicondyle |
| ● 2. Coronoid process | ● 11. Medial border | ● 20. Radial fossa |
| ● 3. Clavicle (Cut) | ● 12. Lateral border | ● 21. Trochlea |
| ● 4. Superior angle | ● 13. Inferior angle | ● 22. Capitulum |
| ● 5. Supraspinous fossa | ● 14. Intertubercular sulcus | ● 23. Lateral epicondyle |
| ● 6. Head of Humerus | ● 15. Deltoid tuberosity | ● 24. Olecranon fossa (humerus) |
| ● 7. Spine of scapula | ● 16. Humerus (Shaft) | ● 25. Medial epicondyle |
| ● 8. Glenoid cavity | ● 17. Lateral epicondyle | ● 26. Groove for Ulna nerve |
| ● 9. Subscapula fossa | ● 18. Coronoid fossa | ● 27. Trochlea (humerus) |



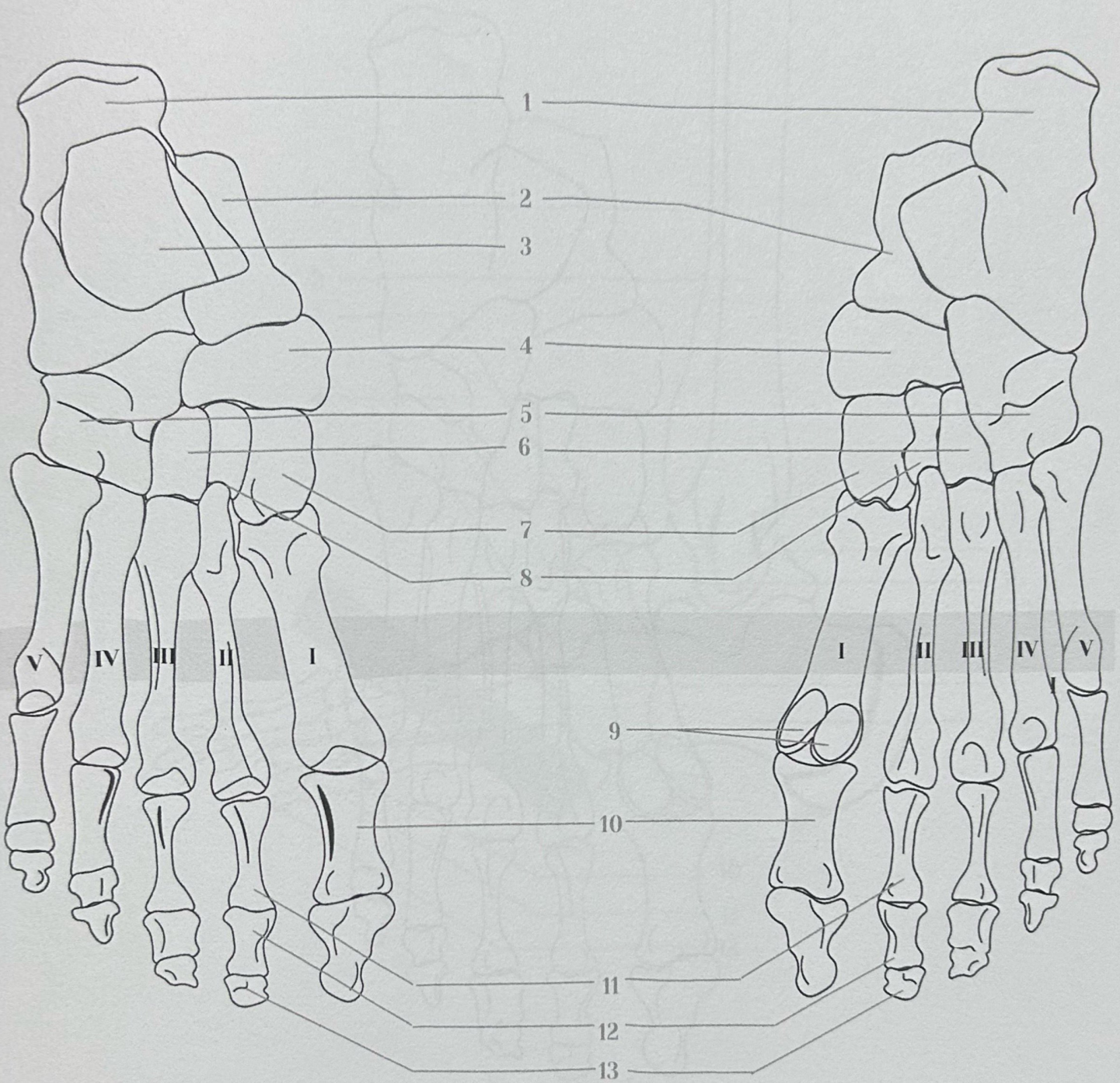
- 1. 5th Metacarpal bone
- 2. 4th Metacarpal bone
- 3. Trapezoid
- 4. Hamate
- 5. Pisiform
- 6. Triquetrum
- 7. 1st Metacarpal bone
- 8. Trapezium
- 9. Capitate
- 10. Scaphoid
- 11. Lunate
- 12. Radius
- 13. Ulna



- | | | |
|---------------------------------|----------------------------------|---------------------------------|
| ● 1. Cervical vertebra (C7) | ● 10. Costal cartilage | ● 19. Inferior angle (scapula) |
| ● 2. 1st Rib | ● 11. Thoracic vertebra (T12) | ● 20. Xiphoid Process (Sternum) |
| ● 3. Acromion (Scapula) | ● 12. Trochlear (humerus) | ● 21. Floating rib |
| ● 4. Humerus (head) | ● 13. Thoracic vertebra (T1) | |
| ● 5. Subscapula fossa (scapula) | ● 14. Clavicle | |
| ● 6. Body (Sternum) | ● 15. Coracoid process (Scapula) | |
| ● 7. Humerus (Shaft) | ● 16. Manubrium (Sternum) | |
| ● 8. 5th Rib | ● 17. 2nd Rib | |
| ● 9. Angle of rib (10th Rib) | ● 18. Sternal angle | |

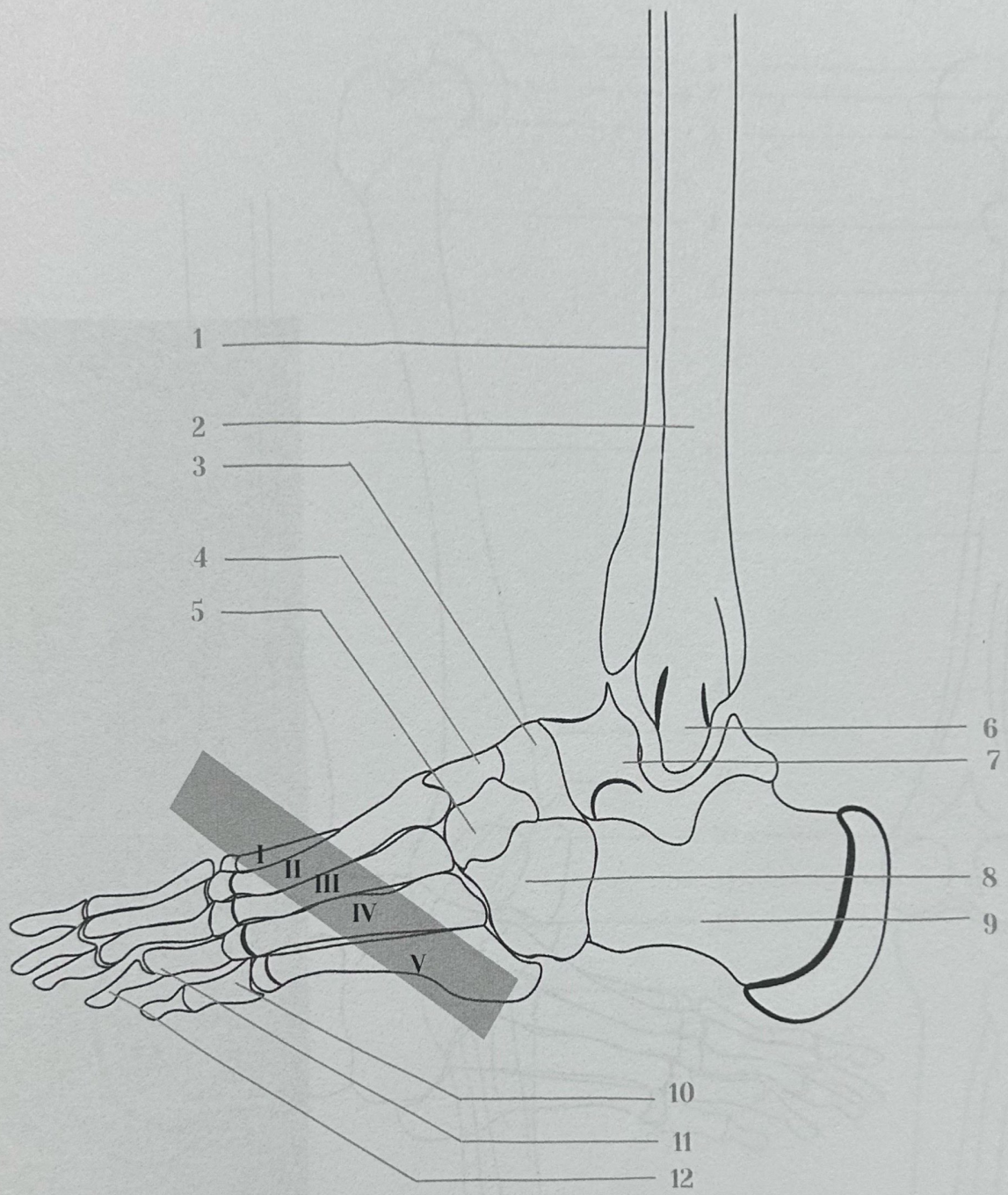
Dorsal view

Plantar view



7 Tarsal Bones

- | | | | |
|-------------------------------------|----------------------------------|---------------------------|------------------------------|
| ● 1. Calcaneus | ● 5. Cuboid Bone | ● (I) 1st Metatarsal bone | ● 10. Proximal phalanx (1st) |
| ● 2. Talus Bone | ● 6. Lateral cuneiform bone | ● (II) 2nd Metatarsal | ● 11. Proximal phalanx |
| ● 3. Articular surface (Femur Bone) | ● 7. Intermediate cuneiform bone | ● (III) 3rd Metatarsal | ● 12. Middle phalanx |
| ● 4. Navicular bone | ● 8. Medial cuneiform bone | ● (IV) 4th Metatarsal | ● 13. Distal phalanx |
| | ● 9. Sesamoid bones | ● (V) 5th Metatarsal | |



- 1. Tibia
- 2. Fibula
- 3. Navicular bone
- 4. Intermediate cuneiform bone
- 5. Lateral cuneiform bone
- 6. Lateral malleolus (fibula)

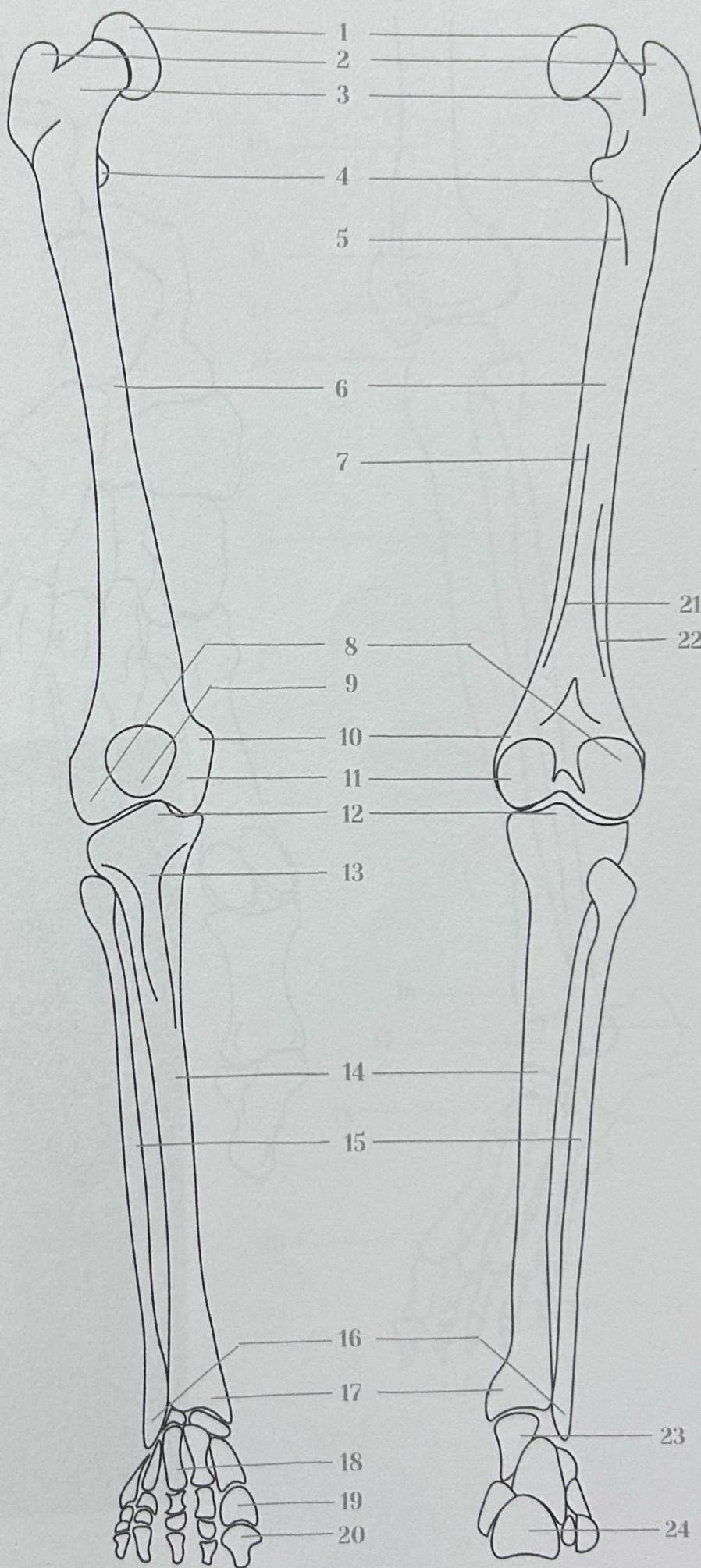
- 7. Talus Bone
- 8. Cuboid Bone
- 9. Calcaneus
- 10. Proximal Phalanx
- 11. Proximal Phalanx
- 12. Distal Phalanx

- (I) 1st Metatarsal bone
- (II) 2nd Metatarsal
- (III) 3rd Metatarsal
- (IV) 4th Metatarsal
- (V) 5th Metatarsal

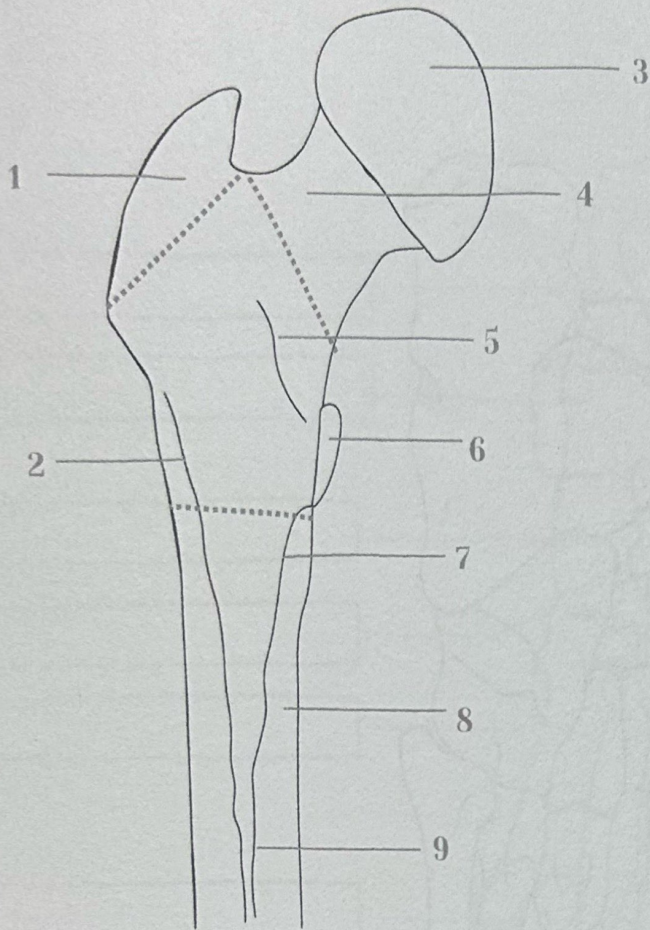
Anterior view

Posterior view

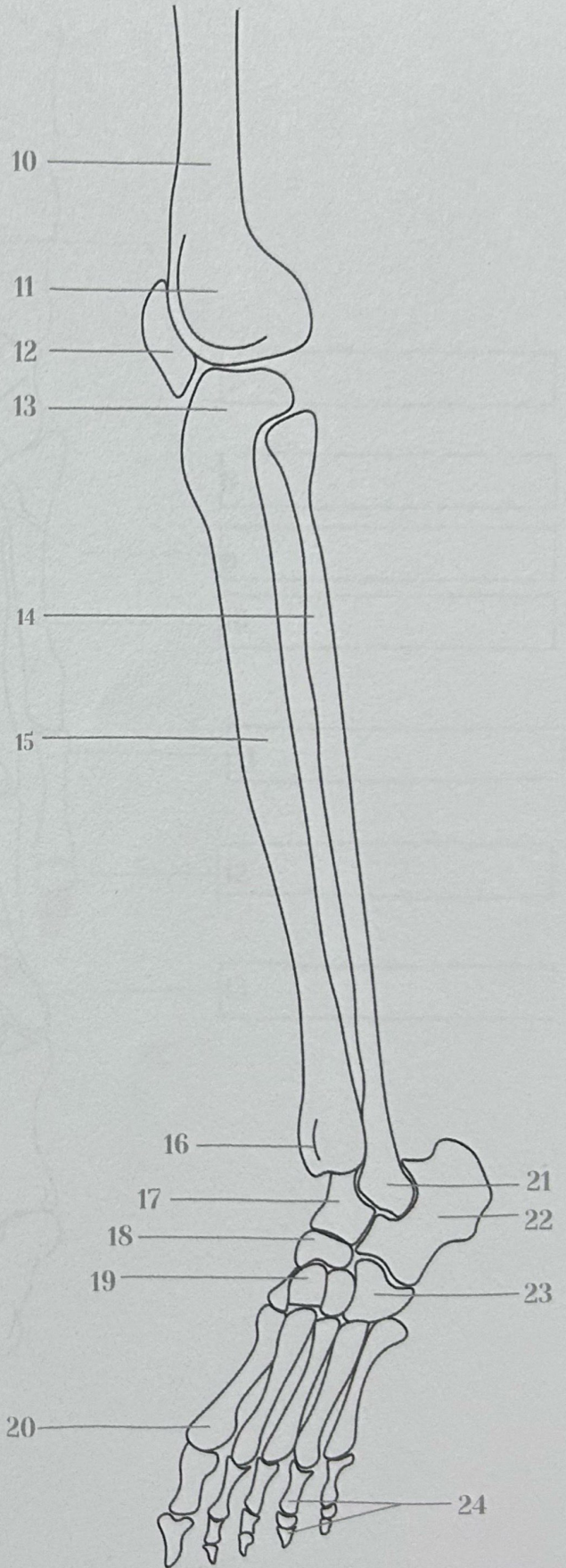
- 1. Head (Femur)
- 2. Greater trochanter (Femur)
- 3. Neck (Femur)
- 4. Lesser trochanter (Femur)
- 5. Pectineal line
- 6. Femur (Shaft)
- 7. linea aspera
- 8. Lateral femoral condyle
- 9. Patella
- 10. Medial epicondyle
- 11. Medial femoral condyle
- 12. Intercondylar eminence
- 13. Tibial tuberosity
- 14. Tibia
- 15. Fibula
- 16. Lateral malleolus (Fibula)
- 17. Medial malleolus (Tibia)
- 18. Metatarsal bones
- 19. Proximal Phalanx (1st)
- 20. Distal Phalanx (1st)
- 21. Medial supracondylar line
- 21. Lateral supracondylar line
- 23. Talus (Tarsal bone)
- 24. Calcaneus (Tarsal bone)



Proximal Femur (Posterior view)



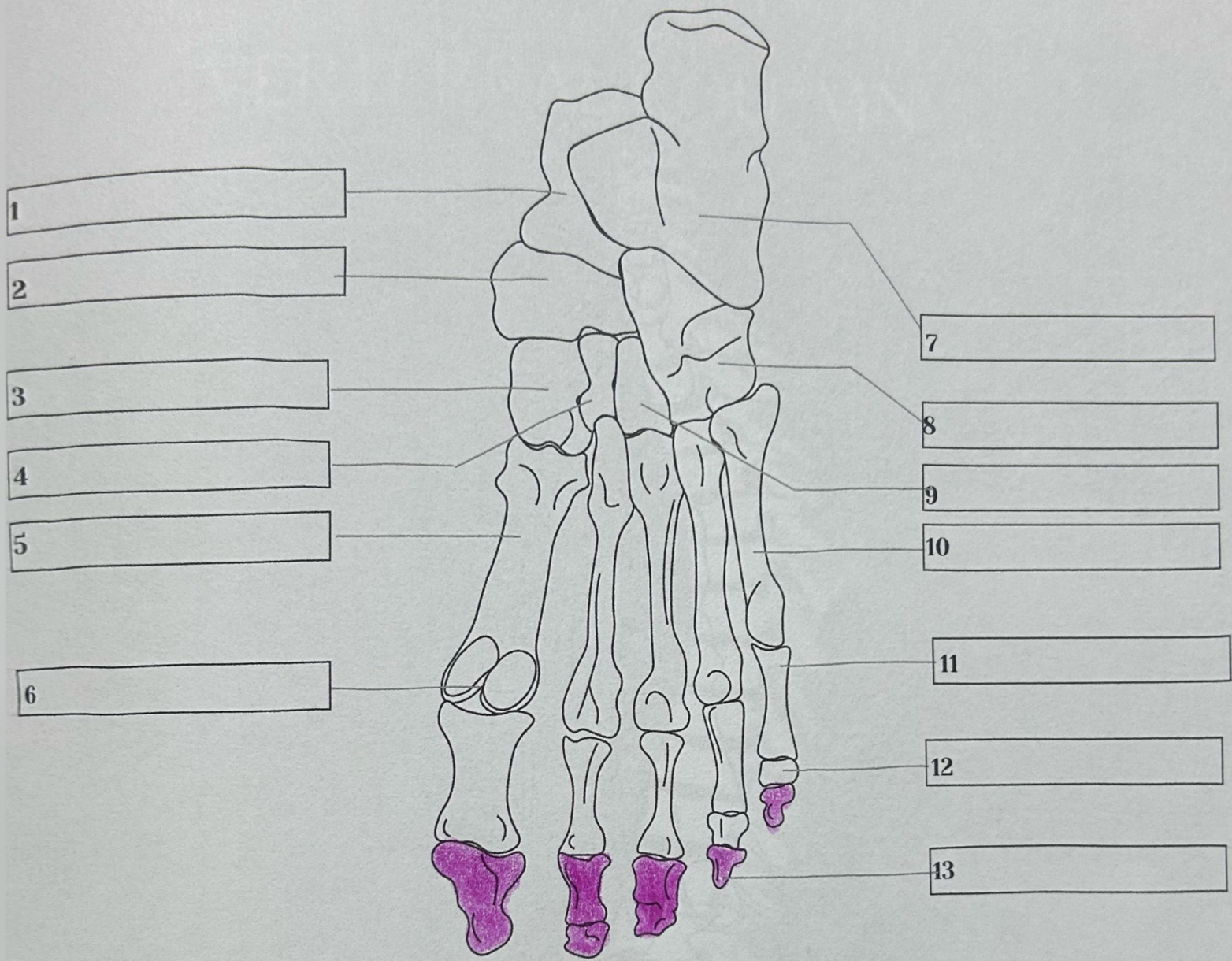
Leg (Anterolateral view)



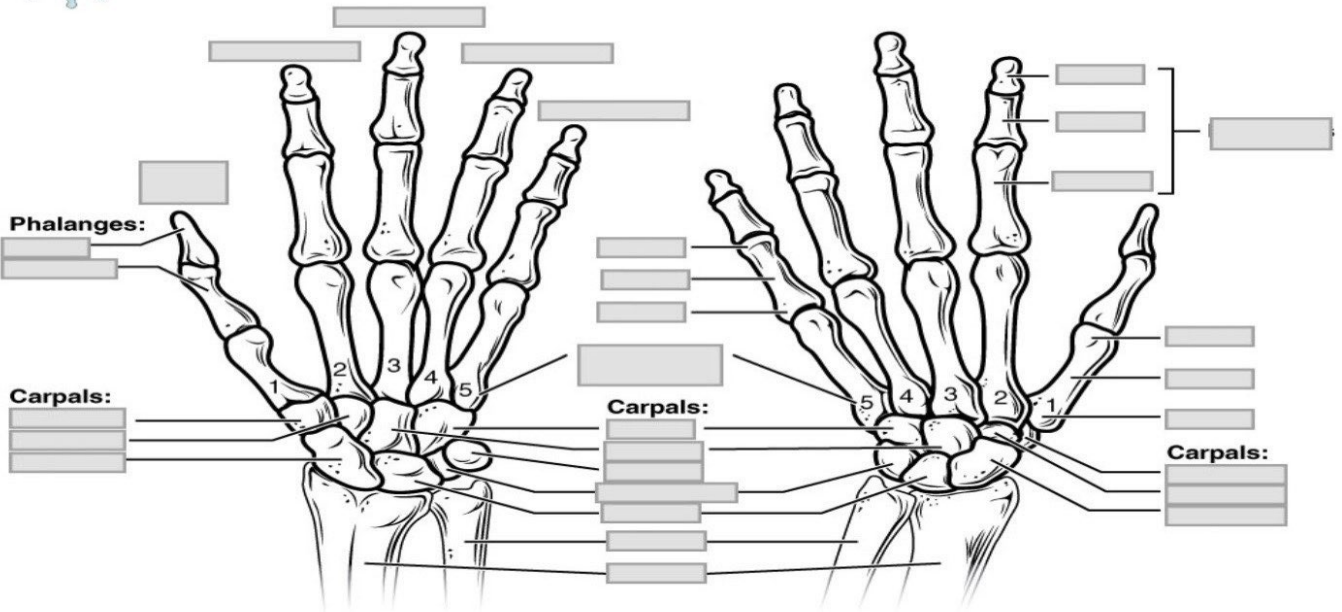
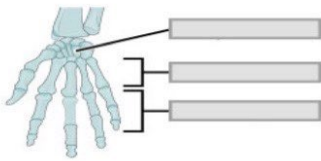
Proximal Femur (posterior view)

Leg (anterolateral view)

- | | |
|-----------------------------|-----------------------------------|
| ● 1. Greater trochanter | ● 10. Distal Shaft (Femur) |
| ● 2. Gluteal tuberosity | ● 11. Lateral condyle of femur |
| ● 3. Head (Femur) | ● 12. Patela |
| ● 4. Neck (Femur) | ● 13. Lateral condyle of tibia |
| ● 5. Intertrochanteric line | ● 14. Fibula |
| ● 6. Lesser trochanter | ● 15. Tibia |
| ● 7. Pectineal line | ● 16. Medial malleolous (Tibia) |
| ● 8. Shaft (Femur) | ● 17. Talus |
| ● 9. Linea Aspera | ● 18. Navicular |
| | ● 19. Cuneiform bone |
| | ● 20. Metatarsal bone |
| | ● 21. Lateral malleolous (Fibula) |
| | ● 22. Calcaneus |
| | ● 23. Cuboid |
| | ● 24. Phalanges |



- 1. Talus
- 2. Navicular
- 3. Medial cuneiform bone
- 4. Intermediate cuneiform bone
- 5. 1st Metatarsal bone
- 6. Sesamoid bones
- 7. Calcaneus
- 8. Cuboid
- 9. Lateral cuneiform bone
- 10. 5th Metatarsal bone
- 11. Proximal phalanx
- 12. Middle phalanx
- 13. Distal phalanx



Anterior view

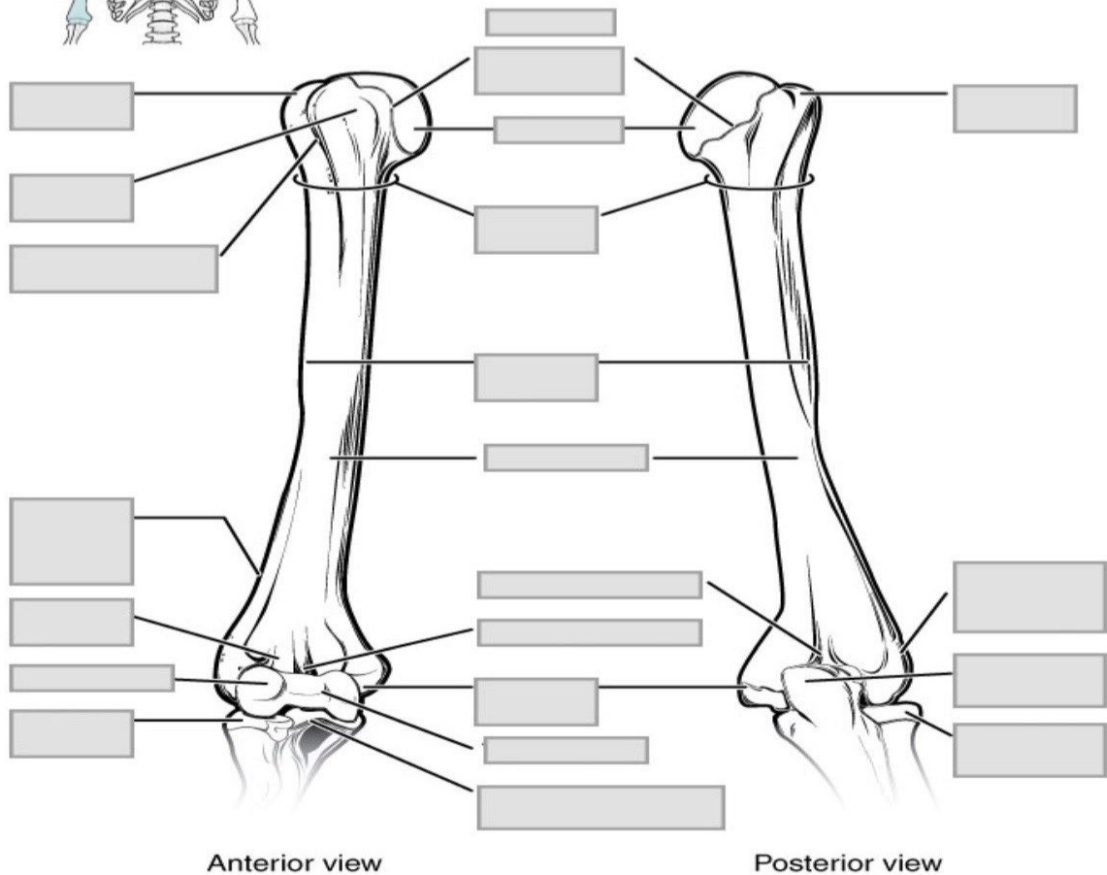
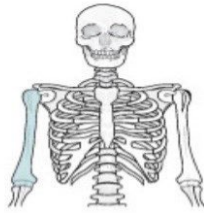Posterior view

- Carpals
- Distal Phalanx
- Metacarpal 1
- Metacarpal 2
- Metacarpal 3

- Metacarpal 4
- Metacarpal 5
- Scaphoid
- Trapezoid
- Trapezium

- Capitate
- Hamate
- Pisiform
- Triquetrum
- Lunate

- Anatomical Neck



- Capitulum
- Coronoid Fossa
- Deltoid Tuberosity
- Greater Tubercle
- Head
- Intertubercular Groove
- Lateral Epicondyle
- Medial Epicondyle
- Lesser Tubercle
- Olecranon Fossa
- Lateral Supracondylar Ridge
- Radial Fossa
- Shaft
- Surgical Neck